

Analysis of Symmetry in Rhomboid Flaps: Comparison of Angles between Standardized Method and Freehand Technique

Análise de simetria em retalhos rombóides: comparação de ângulos entre o método padronizado e a técnica por abordagem livre

Marina Renata Foggiatto¹, Kátia Sheylla Malta Purim¹ & Giuliana Lugarini¹

¹Universidade Positivo Campus Ecoville, Curitiba, Paraná. E-mails: marinarfoggiatto@gmail.com, kspurim@gmail.com & giulianalugarini4@gmail.com.

Resumo: Introdução: O retalho rombóide é utilizado para a remoção de tumores, cistos e correção de cicatrizes. A precisão na sua execução depende da técnica empregada. A sistematização do processo pode reduzir erros e melhorar os resultados. **Objetivo:** Analisar comparativamente a simetria final dos retalhos produzidos por abordagem livre (Grupo 1) e técnica padronizada (Grupo 2). **Métodos:** Estudo observacional e quantitativo. Conduzido na Universidade Positivo, Curitiba-PR, com acadêmicos do 4º ano de Medicina. Divididos em dois grupos (1 e 2) de 20 alunos cada. A reprodução foi em patas de porco. A avaliação da simetria utilizou ângulos, calculados com base no programa computacional Photoshop®. A análise dos dados utilizou estatística descritiva. **Resultados:** Para acadêmicos do grupo 1, os ângulos médios foram: A = 76°, B = 107°, C = 77° e D = 104°. A simetria entre ângulos opostos mostrou que 10% tiveram diferenças maiores que 15°. Entre os ângulos B e D, 30% apresentaram diferenças superiores a 15°. No grupo 2, os ângulos médios foram: A = 66°, B = 114°, C = 68°, e D = 115°. A simetria entre ângulos opostos no grupo com metodização mostrou que apenas 5% tiveram diferenças maiores que 15°. Entre os ângulos B e D, nenhum aluno apresentou diferenças superiores a 15°. **Discussão:** A técnica padronizada resultou em ângulos mais próximos dos valores ideais, com variação reduzida, indicando maior precisão e consistência que a abordagem livre. **Conclusão:** Um protocolo estruturado é fundamental para aprimorar o retalho e garantir resultados consistentes.

Palavras-chave: Retalhos Cirúrgicos; Dermatologia; Educação Médica.

Abstract: Introduction: The rhomboid flap is used for the removal of tumors, cysts, and scar correction. The precision of its execution depends on the technique employed. Systematizing the process can reduce errors and improve outcomes. **Objective:** To comparatively analyze the final symmetry of flaps produced by students using a freehand approach (Group 1) and a standardized technique (Group 2) and those using a standardized method. **Methods:** This is an observational and quantitative study conducted at Universidade Positivo, Curitiba-PR, with fourth-year medical students. They were divided into two groups (1 and 2) of 20 students each. The procedure was performed on pig limbs. Symmetry evaluation was based on angles calculated using a computer program. Data analysis utilized descriptive statistics. **Results:** For Group 1 students, the average angles were: A = 76°, B = 107°, C = 77°, and D = 104°. Symmetry between opposite angles showed that 10% had differences greater than 15°. Between angles B and D, 30% showed differences greater than 15°. In Group 2, the average angles were: A = 66°, B = 114°, C = 68°, and D = 115°. Symmetry between opposite angles in the standardized method group showed that only 5% had differences greater than 15°. Between angles B and D, no student showed differences greater than 15°. **Discussion:** The standardized technique resulted in angles closer to ideal values with reduced variation, indicating greater precision and consistency compared to the freehand technique. **Conclusion:** A structured protocol is essential for improving the flap and ensuring consistent results.

Keywords: Surgical Flaps; Dermatology; Medical Education.

1 INTRODUCTION

The Limberg rhomboid flap is a transpositional flap designed from the drawing of a parallelogram with two 120° angles and two 60° angles, forming equal sides with four lobes (GRAB, 2007; ANCHUNDIA, 2021; MACNEAL, 2024). The pedicle preserves subpapillary and subdermal vascular plexuses, and the incisions must be made parallel to the relaxed skin tension lines to ensure proper healing and an optimal aesthetic outcome.

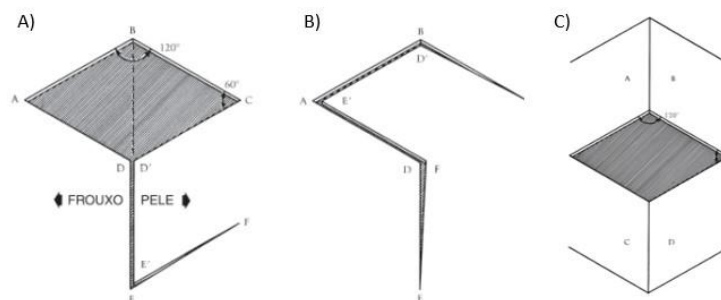
This flap is highly useful in reconstructive surgery for skin cancer of the head and neck (MACNEAL, 2024; BRITO, 2023), as well as in other locations (HOWARD, 2005; ALVAREZ, 2012; KANG, 2021) and defects, such as spina bifida, burn contractures, chronic pilonidal cysts, hand and breast reconstruction (KANG, 2021). It stands out for its safety, versatility, and efficacy in repairing small to medium-sized cutaneous defects. Variations of rhomboid flaps (Dufourmental, Webster, Quaba-Sommerland, double, triple, etc.) offer the surgeon options tailored to each scenario and patient. Moreover, by utilizing the laxity of the adjacent skin to the defect, which shares characteristics similar to the excised tissue, it provides excellent contour, texture, thickness, color matching, and ensures both good cosmetic and functional outcomes. Mastering the nuances of flap design, elevation, and closure optimizes results and minimizes potential complications (MACNEAL, 2024).

Due to its advantages and wide range of clinical applications, the teaching-assessment-learning of this technique is relevant in the training of essential skills for outpatient procedures in both undergraduate and postgraduate surgical education. Therefore, this study comparatively analyzes the final symmetry of rhomboid flaps performed by medical students on pig limbs, produced through a freehand approach (Group 1) and a standardized technique (Group 2).

1.1 Standardized Method for the Rhomboid Flap

The proposed standardized technique is applicable to rhomboid defects, based on 60- and 120-degree angles. The flap features sides of equal length to the shortest axis of the rhomboid defect (GRAB, 2007) (Figure 1).

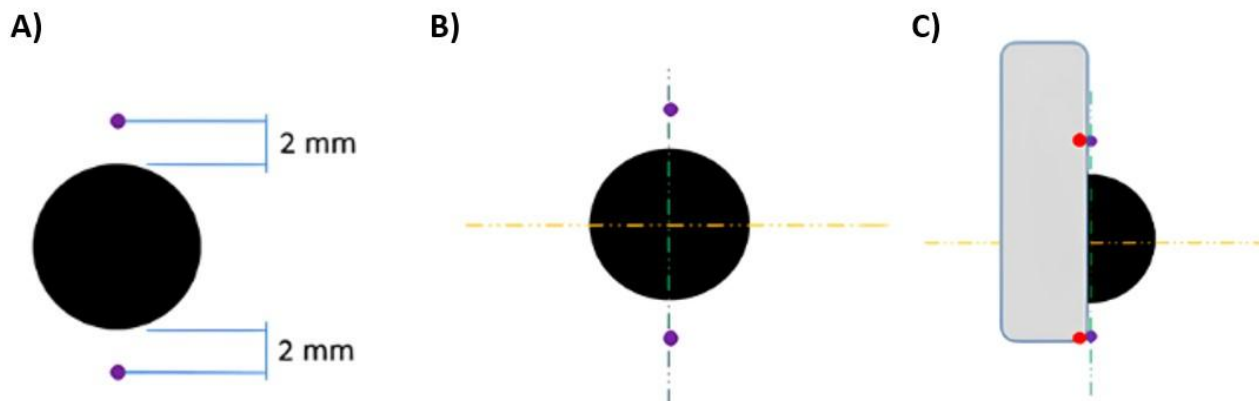
Figure 1- Planning of a Rhomboid (Limberg) Flap



Source: Grabb & Smith (2007)

For its marking, a safety margin of 2 to 3 mm is left from the lesion, marking two points (shown in purple in figure 2A). From these points, a guiding line (in green) is drawn, and perpendicular to it, along the midline of the lesion, another guiding line (in orange) is traced, as shown in figure 2B. This allows the construction of the rhombus, formed by two equilateral triangles joined at their bases. Subsequently, the distance between the two initial points is measured using the thread packaging, which is then replicated in the following steps of the drawing (Figure 2C).

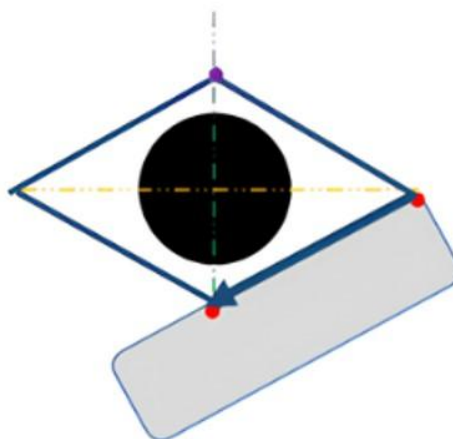
Figure 2- Marking of Reference Points



Source: The authors (2024)

Next, transfer the replicated length from the envelope to the vertical line or the line perpendicular to the guiding lines (in green). This allows for the drawing of the four sides of the rhombus (Figure 3).

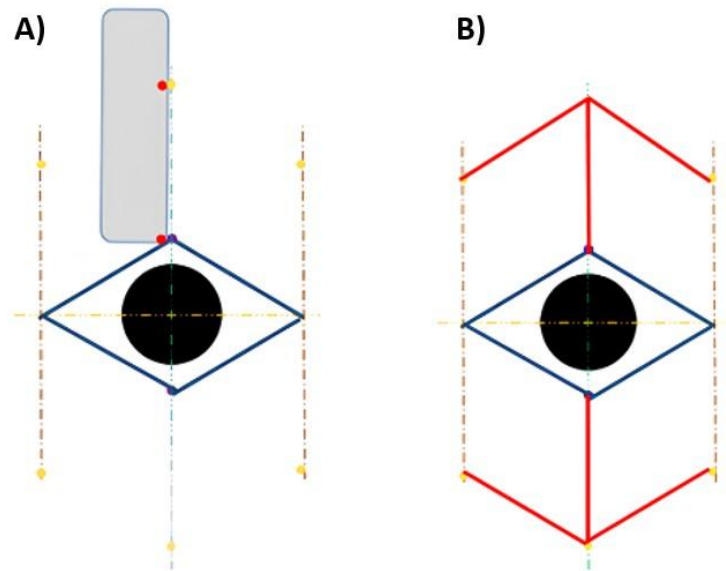
Figure 3- Drawing of the Rhombus Lines



Source: The authors (2024)

Starting from the vertices of the largest dimension of the rhombus and parallel to the first guiding line, another line is drawn in brown. Using the reference from the envelope, transfer its length to the three guiding lines, marking six points (Figure 4A). Connect these points (indicated in yellow), and the lines formed (in red) determine where the incision will be made. Thus, there are four options to choose from (Figure 4 B).

Figure 4- Marking the Guiding Lines



Source: The authors (2024)

2 METHODS

This is an observational, cross-sectional, quantitative study conducted in the Medical Course at Universidade Positivo. The research was approved by the institutional ethics committee (CEP-UP) under CAAE 75435023.7.0000.0093.

Students who were present during the practical class on the rhomboid flap in the outpatient surgery course and who agreed to the Informed Consent Form (ICF) were included in the study. Students who did not complete the flap and those who performed it on synthetic material were excluded.

A non-probabilistic sample was used with two groups: Group 1 (G1), which received only the image of the flap to be reproduced without any methodological guidance on the technique, and Group 2 (G2), which received a detailed presentation of the step-by-step process for drawing the flap (methodology described in section 1.1). All participants were provided with a suture kit (including a scalpel handle, needle holder, anatomical forceps, rat-tooth forceps, scissors, a scalpel blade, and 3-0 nylon sutures), as well as toothpicks and green food coloring to create the flap design.

At the end of the flap procedures, the flaps were photographed alongside the needle envelope used as a reference for comparative measurements. Each flap was assigned a random identification number next to it, preserving the anonymity of the research. After data collection, the photos were organized into folders—one for Group 1 (G1) and another for Group 2 (G2). Each image was then analyzed individually using Photoshop® to measure the angles. The angles A, B, C, and D were calculated individually within the software and labeled identically to those in Figure 1. The data were tabulated in Excel and analyzed comparatively between the two groups using descriptive statistics with Stata software.

3 RESULTS

The sample consisted of 40 medical students (G1=20 and G2=20). For the students who did not follow the methodological guidance (G1), the average angles measured were as follows: Angle A = 76°, Angle B = 107°, Angle C = 77°, and Angle D = 104°. The percentage differences from the desired values were as follows: Angle A, with a target of 60°, showed a difference of 26.67%; Angle B, with a target of 120°, demonstrated a difference of 10.83%; Angle C, also desired at 60°, had a difference of 28.33%; and Angle D, with a target of 120°, exhibited a difference of 13.33%. The symmetry between opposing angles in G1 revealed that 60% of the students had differences of less than 5° between Angles A and C, 35% had

differences between 6-10°, and 10% had differences greater than 15°. For Angles B and D, 35% of the students had differences of less than 5°, 30% had differences between 6-10°, and 30% showed differences exceeding 15°.

In the group that utilized the methodological guidance (G2), the average angles measured were as follows: Angle A = 66°, Angle B = 114°, Angle C = 68°, and Angle D = 115°. The percentage differences for Angle A decreased to 10%, for Angle B it was 5%, for Angle C it was 13.33%, and for Angle D it was 4.17%. The symmetry between opposing angles in G2 showed that 45% of the students had differences of less than 5° between Angles A and C, 35% had differences between 6-10°, and only 5% had differences greater than 15°. For Angles B and D, 30% had differences of less than 5°, 45% had differences between 6-10°, and no students showed differences exceeding 15°.

4 DISCUSSION

In the group that did not follow the methodological guidance (G1), the average angles obtained were significantly different from the established targets. As presented in the results, the average for Angle A showed a percentage difference of 26.67% compared to the ideal angle. Angle B had a difference of 10.83%, Angle C a difference of 28.33%, and Angle D a difference of 13.33%. These values demonstrate that the lack of methodological guidance significantly impacted the accuracy of the measured angles in relation to the targets of 60° for A and C, and 120° for B and D.

On the other hand, the students who followed the methodological guidance (G2) demonstrated more accurate results. The percentage difference for Angle A was reduced to 10% compared to the target, Angle B had only a 5% difference, Angle C showed a difference of 13.33%, and Angle D had a minimal difference of 4.17%. These results indicate a significant improvement in the accuracy of the measured angles with the application of the methodology.

Regarding the symmetry between opposing angles in the group without the prescribed methodology (G1), 60% of the sample showed a difference of less than 5° between Angles A and C, while 35% had differences between 6-10°, and 10% exhibited differences greater than 15°. Concerning the asymmetry between Angles B and D, 35% of the students had differences of less than 5°, 30% had differences between 6-10°, and 30% showed differences exceeding 15°. These data indicate that the lack of methodological guidance resulted in considerable variation in the opposing angles, reflecting a lack of symmetry in the flap.

In the group with methodological guidance (G2), the comparison between the similarity of Angles A and C showed that 45% had differences of less than 5° between them, 35% had differences between 6-10°, and only 5% exhibited differences greater than 15°. For Angles B and D, 30% of the students had differences of less than 5°, 45% had differences between 6-10°, and no students showed differences exceeding 15°. These results suggest that the methodological guidance not only improved the accuracy of the measurements but also reduced the variation between opposing angles, thereby enhancing the consistency and symmetry of the results.

Thus, the standardized technique resulted in angles that were closer to the ideal values, with lower standard deviations and a reduced range of variation, indicating greater accuracy and consistency. In contrast, the non-standardized technique exhibited higher variability and lower precision. When incisions are made correctly, parallel to the lines of tension in relaxed skin, the resulting scar aligns with the skin folds along the line of maximum extensibility, favoring a narrower scar (KANG, 2021). Furthermore, the symmetry of the rhomboid flap allows for the relief of tension lines, leading to improved aesthetic and scar outcomes.

It is of paramount importance to ensure the geometric proportion during its execution (HO W, 2021) aligned with anatomical and mechanical principles. This approach facilitates an effective repair of cutaneous defects, allowing for a functional and harmonious integration with the surrounding skin while minimizing distortions in the structures (SANTOS, 2022).

The execution of this study enabled a comparative analysis of the angles at each vertex, consequently examining symmetry. The comparison between the two groups (G1 and G2), along with the presentation of statistical results, facilitated the interpretation that the implementation of the methodology for executing the rhomboid flap is strongly indicated. This assertion is based on the fact that it resulted in

greater precision and consistency in the angles of the flaps when compared to the non-standardized technique.

The advantages of the rhomboid flap and its superior aesthetic outcomes compared to skin graft reconstruction make it essential for surgical training (BRITO, 2023; KANG, 2021; HARI, 2022), as it is a safe and easy-to-execute flap (SANTOS, 2022). Although there are other didactic and technological resources for surgical education (PURIM, 2015), the step-by-step approach provided by this standardization of the technique allows for a better understanding of the stages, errors during reproducibility, and adjustments with greater dynamism and ease.

Among the limitations of this study are its cross-sectional design and small sample size. However, it is evident that a structured protocol is essential for improving flap outcomes, achieving more consistent and aesthetically pleasing results, and enhancing applicability in the context of medical practice.

5 CONCLUSION

The standardization demonstrated effectiveness in reducing discrepancies and improving the symmetry of the angles of the rhomboid flap. These results suggest that the implementation of a clear and rigorous methodology is crucial for achieving more accurate and consistent measurements.

REFERENCES

- ALVAREZ, G.; LAITANO, F.; SIQUEIRA, E.; OLIVEIRA, M.; MARTINS, P. Aplicações do retalho romboide em reparações cutâneas. *Revista Brasileira de Cirurgia Plástica* [Internet], v.27, n.1, p.102–107, 2012. Disponível em: <https://www.scielo.br/j/rbcp/a/Fkgs3hqq7pdJqDFbxRThDjC/>. Acesso em: 06 fev. 2025.
- ANCHUNDIA GARCÍA, F.; LÓPEZ ROSEL, A.; GUAYA IRIARTE, A.; TAIPE TOPÓN, D. Versatilidade do retalho de Limberg no fechamento de defeitos da pele. *J American Health*, v.4, n.2, p.95-109, 2021. Disponível em: https://www.researchgate.net/publication/373120267_Limberg_flap_a_review.
- BRITO-BRITO, N. R.; GÓMEZ-ALVARADO, A.; ZERMEÑO-TORRES, J.; AUGUSTO, T. T.; RAMÍREZ-MIGUEL, W. O.; GUANOLUISA, S. A.; BERRAZUETA-PEÑAHERRERA, V. E.; BARRERA-MERA, B. Limberg flap: a review. *International Journal of Research in Medical Sciences*, v.11, n.9, p.3495–3497, 2023. Disponível em: <https://www.msjonline.org/index.php/ijrms/article/view/12591>. Acesso em: 30 jan. 2025.
- GRABB, W. C.; SMITH, J. W. *Grabb & Smith Cirurgia Plástica*. 6. ed. 2007.
- HO, W.; JONES, C. D. Geometry and design of a rhomboid flap. *Journal of Plastic Surgery and Hand Surgery* [Internet], v.55, n.4, p.249–254, 2021. Disponível em: <https://pubmed.ncbi.nlm.nih.gov/33480812>. Acesso em: 30 jan. 2025.
- HOWARD, M. A.; MEHRARA, B. Emerging trends in microsurgical breast reconstruction: Deep inferior epigastric artery perforator (DIEP) and the superior gluteal artery perforator (SGAP) flaps. *International Journal of Surgery*, v.3, n.1, p.53–60, 2005.
- KANG, A. S.; KANG, K. S. Rhomboid flap: Indications, applications, techniques and results. A comprehensive review. *Annals of Medicine and Surgery*, v.68, p.102544, 2021.
- MACNEAL, P.; HOHMAN, M. H.; ADLARD, R. E. Rhombic Flaps. In: *StatPearls* [Internet]. Treasure Island (FL): StatPearls Publishing; 2024 Jan–. 2024 Apr 18. Disponível em: <https://europepmc.org/article/NBK/nbk558931>. Acesso em: 06 fev. 2025.
- PURIM, K. S. M.; SKINOVSKY, J.; FERNANDES, J. W. Habilidades básicas para cirurgias ambulatoriais na graduação médica. *Revista do Colégio Brasileiro de Cirurgiões*, v.42, n.5, p.341–344, 2015.
- SANTOS, A. D.; HADDAD FILHO, D.; MARCELINO, F. F.; VIEITES, L. Applicability of the Limberg flap: a case series. *Surgical & Cosmetic Dermatology*, v.14, p.249–253, 2022.